

# Healing of acute wounds treated with green propolis-based powder product


*Cicatrização de feridas agudas tratadas com produto em pó à base de própolis verde*

*Cicatrización de heridas agudas tratadas con producto en polvo a base de propóleo verde*


## Abstract

**Objective:** To evaluate the healing potential of a green propolis-based powder product on acute lesions induced in rats. **Method:** This is an experimental study conducted with 27 Wistar lineage rats randomly divided into three groups. The lesions were surgically induced and treated every 48 hours with the test products (green propolis-based powder, Brava Ostomy Powder™, and saline solution). The lesions were analyzed macroscopically and microscopically on the 7th, 9th, and 11th postoperative days. **Results:** Most of the lesions treated with green propolis-based powder healed in 11 days. The product formulated for this study and the commercial one showed satisfactory results in wound retraction, anti-inflammatory activity, angiogenesis, fibroblast proliferation, and collagen synthesis. **Conclusion:** Treatment with the green propolis-based product showed great potential for healing skin lesions. **Keywords:** Propolis; Wounds and injuries; Wound Healing; Pharmacognosy.


Talita Faraj Faria<sup>1</sup>

 0000-0002-3690-2968


Roberta Faraj Faria<sup>1</sup>

 0000-0001-7272-5316

Ivone Kamada<sup>1</sup>

 0000-0003-2569-8727

Lívia Cristina Lira de Sá Barreto<sup>1</sup>

 0000-0001-8197-4349

<sup>1</sup>University of Brasilia, Brasilia, Federal District, Brazil.

## Resumo

**Objetivo:** avaliar o potencial cicatrizante de um produto em pó à base de própolis verde em lesão aguda induzida em ratos. **Método:** trata-se de um estudo experimental realizado com 27 ratos da linhagem *wistar* divididos aleatoriamente em três grupos. As lesões foram induzidas cirurgicamente e tratadas a cada 48 horas com os produtos em teste (pó à base de própolis verde, Brava Ostomy Powder® e soro fisiológico). As lesões foram analisadas macroscópica e microscopicamente no 7º, 9º e 11º dia de pós-operatório. **Resultados:** a maioria das lesões tratadas com pó à base de própolis verde cicatrizou em 11 dias. O produto formulado para este estudo e o comercial mostraram resultados satisfatórios na retração das feridas, atividade anti-inflamatória, angiogênese, proliferação de fibroblastos e síntese de colágeno. **Conclusão:** o tratamento com o produto formulado à base de própolis verde mostrou grande potencial de cicatrização das lesões cutâneas. **Descritores:** Própolis; Ferimentos e lesões; Cicatrização; Farmacognosia.

## Resumen

**Objetivo:** evaluar el potencial cicatrizante de un producto en polvo a base de propóleo verde en heridas agudas inducidas en ratos. **Método:** se trata de un estudio experimental realizado con 27 ratas *wistar*, que se separaron de forma aleatoria en tres grupos. Las heridas quirúrgicas fueron tratadas cada 48 horas con los productos en prueba (polvo a base de propóleo verde, Brava Ostomy Powder® y solución fisiológica). Las heridas se evaluaron macro y microscópicamente a los 7, 9 y 11 días postoperatorios. **Resultados:** la mayoría de las heridas tratadas con el polvo a base de propóleo verde cicatrizaron en 11 días. El producto formulado para este estudio y el producto comercial mostraron resultados satisfactorios en la retracción de heridas, actividad antiinflamatoria, angiogénesis, proliferación de fibroblastos y síntesis de colágeno. **Conclusión:** el tratamiento con el producto a base de propóleo verde mostró un gran potencial curativo de las lesiones cutáneas. **Palabras clave:** Própolis; Heridas y lesiones; Cicatrización de Heridas; Farmacognosia.

Corresponding author:

Talita Faraj Faria  
E-mail: talitafaraj@gmail.com

## INTRODUCTION

Acute wounds originate suddenly from traumas or surgeries. Tissue repair requires less time than injuries considered chronic, as no complications interfering with this process occur during the healing phases<sup>(1)</sup>. Injuries trigger a multifaceted healing process, involving simultaneous and interdependent chemical, biological, and physical activities. This process varies based on the injury's type (acute or chronic), location, and the treatment applied<sup>(2)</sup>.

Since 300 BC, propolis, a resinous substance made by bees (most commonly *Apis mellifera*) from tree, plant, and leaf exudates and flower pollen mixed with saliva, has been used to treat various ailments, including skin lesions. Besides its medicinal use, bees use this resin in hives for insulation, to maintain a temperature around 35°C, to protect against intruding insects, and to seal openings<sup>(3-4)</sup>. Propolis color varies from yellow, red, brown, to green, depending on its source and the surrounding vegetation. Green propolis, prevalent in Argentina, Uruguay, and Brazil, is primarily derived from wild rosemary (*Baccharis dracunculifolia* DC, *Asteraceae* family), or 'common broom.' It contains prenylated derivatives of p-coumaric acid, artemillin C (3,5-diprenyl-4-hydroxycinnamic acid), diterpenes, triterpenes, and flavonoids<sup>(4-6)</sup>.

Propolis contains over 300 chemical elements, regardless of its type, including flavonoids, vitamins E, C, and B complex, minerals like iron, zinc, calcium, and potassium, fatty and phenolic acids, proteins, aromatic aldehydes, alcohols, and amino acids. These components vary based on the propolis's botanical and geographical origins and give the resin its antimicrobial, anti-inflammatory, antioxidant, anesthetic, immunomodulatory, and healing properties, among others<sup>(6-7)</sup>. In Brazil and many other countries, interest is increasing in using propolis, either as an extract from the raw resin or in other forms like creams, ointments, gels, shampoos, or wound dressings, due to the synergistic effects

of its various chemical compounds that give it beneficial properties<sup>(6-8)</sup>.

Treating skin lesions poses a significant challenge for health professionals because of the socioeconomic impact on affected individuals, their families, and health services. This study aims to develop a stable, safe, and effective pharmaceutical formulation using green propolis for *in vivo* skin lesion treatment, with the ultimate goal of applying this resource in humans. The goal is for the product developed from this research to become a future treatment option for skin lesions, including peristomal dermatitis, a common complication in individuals with stomas. Irritative peristomal dermatitis occurs when skin contact with digestive enzymes and electrolytes in waste (feces and urine) causes damage ranging from erythema to skin discontinuity. Traumatic peristomal dermatitis refers to a superficial lesion affecting the dermis, caused by removing the adhesive plate from the collection equipment<sup>(9)</sup>.

Given the complexity of skin lesion treatments and properties of this bee-produced resin, the current study aimed to assess the healing potential of a powder product made from hydroalcoholic extract of green propolis on acute lesions induced in rats.

## METHOD

This experimental pre-clinical study involved 27 adult Wistar rats from the Animal Facility of the Faculty of Medicine, University of Brasília (FM/UnB). Only healthy male animals were selected to ensure sample homogeneity and to prevent hormonal changes from affecting the results. The study was approved by the Ethics Committee on Animal Use (CEUA) of the University of Brasília (opinion number 80/2018) and conducted in stages, including propolis-based product development, *in vivo* testing, and histological analysis. The *in vivo* and histological analysis phases ran from March 2019 to October 2020, after receiving a favorable opinion for the research execution.

## Dressing production

The Mel do Sol company provided a sample of green propolis extract (lot 74/17). At the Laboratory of Drug, Food, and Cosmetics Technology (LTMAC) of the University of Brasília, an 11% hydroalcoholic extract of green propolis and an acrylic copolymer (Eudragit L100) solution was prepared. This solution was then converted into microparticles via a drying process using a Spray Dryer (Labmaq, MSD 1.0), without external environment contact. These microparticles were then mixed in a mortar (PRP: EuL100, at a 1:3 w/w ratio) and combined with sodium carboxymethylcellulose.

The antioxidant activity of this formulation was determined using the DPPH (2,2-diphenyl-1-picrylhydrazyl), ABTS (2,2'-azino-bis [3-ethylbenzothiazoline-6-sulfonic acid]), and TBARS (Thiobarbituric Acid Reactive Species) methods. The DPPH method measured the 2,2-diphenyl-1-picrylhydrazyl free radical scavenging by the substance of interest, expressed as TEAC (Trolox Equivalent Antioxidant Capacity). The green propolis-based product was evaluated in serial dilutions until a high percentage of discoloration, inversely proportional to the Trolox value and corresponding to higher antioxidant activity, was found. The DPPH method also determined the concentration of the studied pharmaceutical formulation required to inhibit 50% of free radical activity.

The ABTS method measured the developed product's antioxidant activity in serial dilutions by capturing the 2,2'-azino-bis(3-ethylbenzothiazoline-6-sulfonic acid) radical generated from oxidation with potassium persulfate salt, reduced in the presence of hydrogen-donating antioxidants. Because it is soluble in water or organic solvents, the ABTS radical can determine both lipo- and hydrophilic products' antioxidant activity. Its values are also expressed according to the TEAC. The TBARS method quantified malondialdehyde (MDA), a biological marker of oxidative damage used to evaluate lipid peroxidation extent observed in free radical chain reactions.

The morphological evaluation, as well as the tests to evaluate the product's rheological characteristics and effectiveness produced for this research, followed the current legislation and the National Health Surveillance Agency (ANVISA) and the Ministry of Agriculture, Livestock, and Supply (MAPA) recommendations for using propolis in pharmaceutical formulations.

The researchers purchased the synthetic resin powder for stomas (Brava Ostomy Powder™) from the Coloplast company (lot 5201536) and used it as positive control group in this study. Its formulation includes carboxymethylcellulose (CMC), guar gum, and xanthan gum. Due to a lack of market-available products with the same characteristics as the developed propolis-based product at the time of data collection, and after analyzing its chemical composition, it was decided to use the aforementioned synthetic resin powder. It has the same presentation as the test product and is used for treating skin lesions, such as peristomal irritative dermatitis.

A chorioallantoic membrane assay (HET-CAM) was also performed in duplicate with 30 chicken embryos on the 8th day of incubation to verify the created product's toxicity as a substitute for the *in vivo* test for evaluating pharmaceutical formulations' toxicity and irritative potential. The chorioallantoic membrane was exposed and moistened with a saline solution for 20 seconds. Subsequently, 50g samples of the test products were added: developed product (11% propolis extract; PE11), commercial product (Brava Ostomy Powder™; CP) composed of 0.1M sodium hydroxide aqueous solution (positive control group; PCG), and 0.9% saline solution (negative control group; NCG), again for 20 seconds. After the established time, the test product samples were removed, and the occurrence of hemorrhage, hyperemia, and coagulation in the membrane was evaluated for 20, 130, and 200 seconds.

After performing the necessary analyses of both the PE11 and CP, the next step was the *in vivo* test.

### Surgical procedure for lesion induction

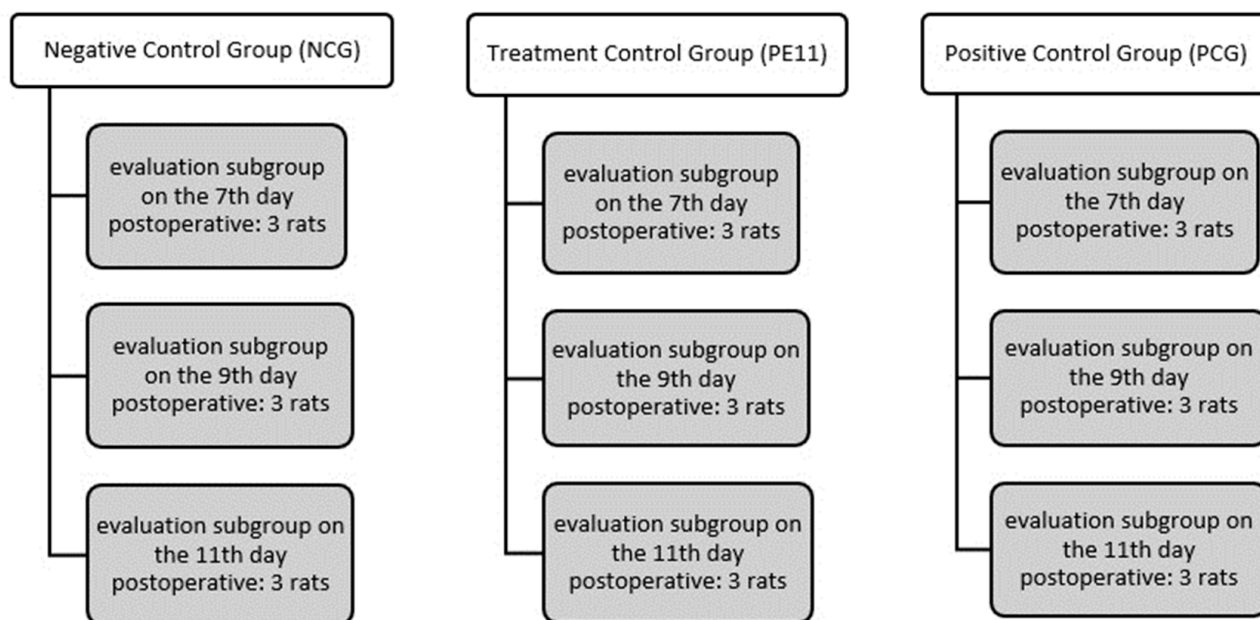
The rats were housed in appropriate conditions, accommodated in polypropylene cages (dimensions 35 cm x 50 cm x 20 cm), and underwent a seven-day acclimatization period in the animal facility, with controlled ambient temperature (22°C), photoperiod (12h light/12h dark), and humidity varying between 50 and 60%. They all received a balanced diet and water *ad libitum* during the experiment.

After the acclimatization period, the animals, now eight weeks old, were weighed for drug dose calculation, presenting body weights ranging from

270g to 380g. Sedation was performed with 10% ketamine hydrochloride and 2% xylazine hydrochloride (at doses of 100mg/kg and 10mg/kg, respectively) via intraperitoneal injection. Then, the animals were positioned in dorsal recumbency, and the hair on their backs was shaved in a 16 cm<sup>2</sup> area; local antisepsis was performed with 70% alcohol and 2% iodinated alcohol.

The lesions were surgically induced on the back using a sterile 6 mm diameter metal punch and a No. 22 scalpel blade to expose the muscle fascia. The rats were randomly allocated into three groups, as shown in Figure 1.

**Figure 1** – Flowchart of the division of groups and subgroups for evaluation, Brasília-DF, 2019.



All animals were given dipyrone (0.1 mL subcutaneously) for pain control 24 hours after wound creation. The wounds were left to heal by secondary intention and dressings were changed every 48 hours according to the study protocol: wounds were cleaned with 0.9% saline solution at room temperature using a 25 x 0.8 mm needle attached to a 20 mL syringe; test products, either PE11, PC, or NCG, were applied to cover the entire wound bed. Wounds were not occluded with secondary dressings and no sedation was used during dressing changes.

Veterinarians supervised the entire experiment and, together with researchers, decided to

end it on the 11th postoperative (PO) day due to the animals' size and weight, prioritizing their well-being as per current legislation on animal research.

### Macroscopic evaluation

Rats were numbered 1 to 27 on their tails for macroscopic evaluation and dressing application control. Three animals were housed per cage to maintain socialization and well-being as advised by the veterinarians. The wound assessment triad created by Dowsett et al. in 2015 was used for macroscopic evaluation, considering wound bed, edges, and adjacent skin characteristics.



A Likert scale was applied to assess wound bed tissue, exudate, and crust presence, with values of 0 (absent), 1 (25% present), 2 (50% present), 3 (75% present), and 4 (100% present).

Morphometric analysis involved periodic measurements of lesion length and width using a disposable ruler, and photographic records at each dressing change. ImageJ software was used to calculate areas, and data were recorded in a Microsoft Excel spreadsheet for analysis.

### Histological evaluation

On days 7, 9, and 11 of treatment, 3 rats from each group were sedated, and tissue fragments with 1 cm of intact border and depth reaching the muscular fascia were collected using a #22 scalpel for histological slide preparation. The animals were then euthanized in a carbon dioxide chamber, and their carcasses were placed in identified white bags for appropriate disposal after waste treatment.

Samples were stained with hematoxylin-eosin (HE) and picosirius for fibroblast proliferation, collagen deposition, neovascularization, and inflammatory infiltrate evaluation using optical microscopy by a blinded, experienced histologist. A Likert-type scale was applied to all variables, considering values from 0 to 3, with 0 for absent, 1 for mild, 2 for moderate, and 3 for intense.

### Statistical analysis

Statistical analysis was performed using Statistical Package for the Social Sciences™ (SPSS) version 23.0 for Microsoft Windows. Multivariate and qualitative data were analyzed using the chi-square test. Pearson's correlation coefficient assessed the association between lesion length and width. ANOVA and Tukey's test were used for lesion area and studied group variables comparison, as well as wound area means comparison, after verifying normality assumptions with the Shapiro-Wilk test. The statistical significance level was set at 5%.

## RESULTS

The developed product's antioxidant activity was assessed, showing DPPH, ABTS, and TBARS values

of  $531.87 \pm 21.82 \mu\text{mol Trolox/mg}$ ,  $1178.90 \pm 114.24 \text{ mM Trolox/mg}$ , and  $64.09 \pm 8.83\%$ , respectively. Morphological and rheological evaluations confirmed the green propolis-based product's effectiveness for in vivo testing. The HET-CAM assay indicated non-severe irritant reactions for both the PE11 and CP compared to PCG and NCG, deeming them safe for lesion application.

Animals recuperated well from anesthetic and surgical procedures with no deaths or unexpected complications. Most PE11 group animals exhibited healed lesions, allowing for uncompromised data analysis when ending the experiment.

Macroscopic surgical wound evaluations were conducted immediately postoperatively (POI) and on PO days 3, 5, 7, 9, and 11, revealing the following healing process characteristics: at POI, all animals ( $n=27$ ) had muscular fascia-reaching lesion depths and experienced post-wound creation bleeding, which ceased during the POI. No bleeding was observed during subsequent dressing changes.

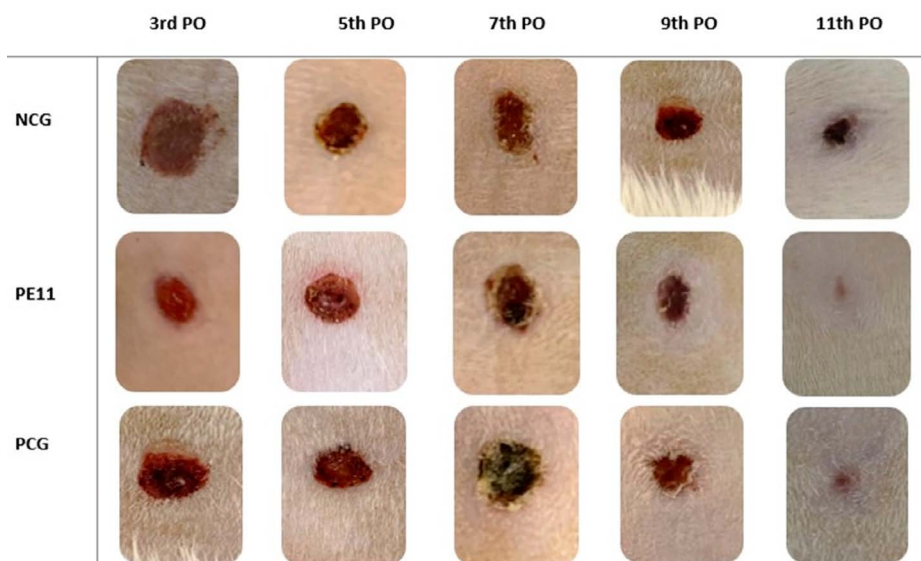
Granulation tissue was visible in all animals ( $n=27$ ) from day three onwards, maintaining a bright red yet slightly dry color despite environmental exposure during dressing changes.

From day three, all groups exhibited thin yellowish crusts covering lesion beds, especially in NCG ( $n=9$ ), where crusts covered the entire bed of the lesions. These crusts could be removed by mechanical debridement without complications.

From day seven, necrosis appeared in some lesions of all groups (NCG  $n=2$ , PE11  $n=1$ , PCG  $n=1$ ), requiring partial devitalized tissue removal before test product application. On day nine, 25% of lesion beds in all groups (NCG  $n=2$ , PE11  $n=1$ , PCG  $n=1$ ) had necrosis, and by day 11, only one NCG rat had necrosis.

Throughout the experiment, all animals in all groups maintained regular, adhered lesion edges without detachment or signs of wound edge rolling (epibole). The perilesional region remained intact for the entire 11-day evaluation period. Figure 2 illustrates lesion evolution by PE11 from days 3 to 11.

**Figure 2** – Macroscopic aspects of the lesions in the negative control group (NCG), treatment group (PE11), and positive control group (PCG). Brasília-DF, Brazil, 2019.



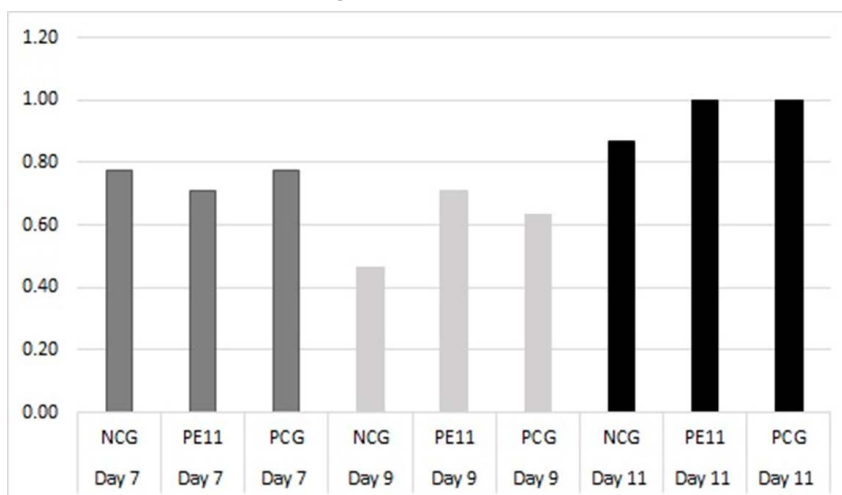
During the study, there was no evidence of infection in any of the animal wounds across all three groups, which would be indicated by symptoms such as purulent exudate, odor, changes in granulation tissue color, bleeding, edema, biofilm formation signs, or hyperemia with local heat around the wound.

Statistically significant differences were found between the PE11 and PCG groups compared to the placebo (NCG) in terms of granulation tissue ( $p=0.023$ ) and epithelial tissue ( $p=0.041$ ). However, there was no significant difference among the groups concerning devitalized tissue ( $p=0.67$ ), crusts ( $p=0.061$ ), and exudate ( $p=0.343$ ).

From the 3rd PO day, all wounds in the three groups ( $n=27$ ) were superficial. Wound contraction was noted from the third day in all groups. A positive linear relationship between wound length and width from the 7th to the 11th PO day was observed in all groups (Figure 3).

The lesion areas on the 7th, 9th, and 11th PO days showed statistically significant differences, with  $p$ -values less than 0.05 ( $p= 0.00$  for days 7 and 9;  $p= 0.03$  for day 11). When comparing the average lesion areas, a significant difference was found between PE11 and PCG versus NCG, as indicated by  $p$ -values less than or equal to 0.05 (Table 1).

**Figure 3** – Correlation between wound length and width. Brasília-DF, Brazil, 2019.



**Table 1** – Comparison of the average lesion areas among the three study groups. Brasília-DF, Brazil, 2019.

Evaluation day	Treatment		Average lesion areas (cm <sup>2</sup> )	Standard error	p-value
7	NCG* (SS 0.9%)	PE11†	0.095	0.01679	0.00
		PCG‡	0.068	0.01679	0.03
9	NCG (SS 0.9%)	PE11	0.108	0.01473	0.00
		PCG	0.983	0.01473	0.00
11	NCG (SS 0.9%)	PE11	0.053	0.01700	0.04
		PCG	0.050	0.01700	0.05

\*NCG – Negative Control Group; †PE11 – Treatment Group (11% propolis extract); ‡PCG – Positive Control Group; SS – Saline Solution

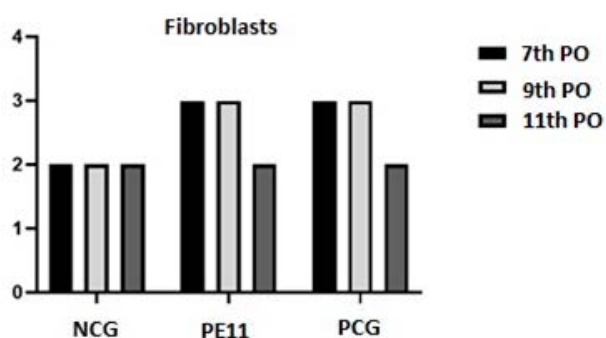
By the end of the experiment on the 11th-day post-operation (PO), 66.66% (2 out of 3) of the lesions in the PE11 and 33.33% (1 out of 3) in the PCG were completely healed, while all the animals in the NCG only showed partial healing.

Histological analysis revealed intense inflammatory infiltrates, such as mono and polymorphonuclear cells, in the NCG on the 7th PO, which moderated on the 9th and 11th PO. The PE11 and PCG showed moderate infiltrates on the 7th and 9th PO but reduced on the 11th PO.

Fibroblast levels were moderate in the NCG throughout, whereas in the PE11 and PCG, they were intense on days 7 and 9. Intense collagen deposition was observed in the PE11 and PCG on all days, as illustrated in Figure 4.

Statistical significance was noted between the PE11 and PCG versus the NCG for fibroblasts ( $p=0.00$ ), collagen synthesis ( $p=0.00$ ), and neovascularization ( $p=0.01$ ), but not for inflammatory infiltrates ( $p=0.06$ ).

**Figure 4** – Fibroblast presence on days 7, 9, and 11 postoperative in the negative control (NCG), treatment (PE11), and positive control (Brava Ostomy Powder™) groups. Brasília-DF, Brazil, 2019.



Source: Research data.

Both the PE11 and PCG stimulated new vessel formation, predominantly on the 7th and 9th PO.

## DISCUSSION

The antioxidant activity of the product developed for this study aligns with another study. Baysan, Elmas, and Koç (2019) reported IC<sub>50</sub> (half-maximum inhibitory concentration) values resembling ours (between 215.23±19.57 and 724.52±2.09mg.g<sup>-1</sup>)<sup>(10)</sup>, as did the results of the ABTS and TBARS methods applied to green, brown, and red propolis-based microparticles, which ranged from 10623.48±69.85 to 15042.12±55.56 μmol de Trolox/mg, respectively<sup>(11)</sup>. These findings allowed us to apply the developed dressing, whose biological safety was also confirmed through the HET-CAM assay, to surgically induced lesions in rats.

Wound treatment remains a challenge for nurses despite recent technological advancements. This is due to various available products, their distribution, individual response variations, and treatment adherence. Although there are anatomical, immunological, and morphological differences, the use of rats in skin repair studies is justified by the similarity of healing phases like inflammation, proliferation, and remodeling<sup>(12)</sup>.

In this study, lesions remained exposed throughout data collection due to occlusive dressing challenges. Keeping three animals per cage allowed socialization but reduced the chances of product removal from the lesions. Researchers stayed in the vivarium longer to ensure maximum product-lesion contact.

Maintaining wound moisture is obtained through occlusive dressings. Dry lesion beds alter growth factor production, impeding angiogenesis and epithelization, causing devitalized tissue (necrosis) due to hypoxia. This delays tissue repair<sup>(13)</sup>, as observed in some animals from the 7th PO onwards, which can partially be attributed to environmental exposure of the lesions.

A 2021 preclinical study by Amorim et al. evaluated different dressing fixation products in mice, such as crepe bandages, self-adhesive bandages, microporous tape, and transparent polyurethane film. They recommended using transparent polyurethane film as primary coverage (3 cm long x 15 cm width; vertical x horizontal), as it maintained dressing integrity for 48 to 96 hours<sup>(14)</sup>. These authors also advised future animal studies to use blindfold testing for this material, encompassing all ideal dressing principles described in the literature.

The macroscopic analysis of the animal surgical wounds revealed satisfactory healing effects for both the green propolis-based powder and the Brava Ostomy Powder™ products. On the 11th PO, the PE11 group had more completely healed animals than the PCG, indicating slightly higher efficacy of the green propolis-based dressing.

A 2021 study by Coelho et al. comparing latex protein bio-membrane and powder hydrocolloid in diabetic foot ulcer patients revealed similar healing rates for both products, indicating no detrimental effects on scarring in either group<sup>(15)</sup>.

In this study, the powder products used in the PE11 and PCG did not show significant negative effects on tissue repair. Only a partially covered crust was observed on the lesion beds of both groups, which was easily removable during dressing changes.

Measuring skin lesions is crucial for assessing healing potential and treatment response<sup>(16)</sup>. Evaluating lesion areas and comparing average areas showed satisfactory effects of both the PE11 and PCG on wound healing, as areas progressively reduced over time.

Regardless of the method used to measure wounds, it is crucial to maintain evaluation techniques throughout the tissue repair process to ensure standardization, objectivity, and accuracy.

Regarding the healing time, most injuries treated with the green propolis-based powder healed in 11 days. This outcome aligns with other studies using this resin, which showed a total healing time between 10 and 15 days. This is the average time for collagen fiber realignment and increased resistance of the newly formed tissue<sup>(17-19)</sup>.

The microscopic analysis revealed that both the products used in the PE11 and PCG groups were biocompatible and did not exert deleterious effects on the lesions, such as causing intense and prolonged inflammatory reactions. The inflammatory reactions observed in the PE11 and PCG were mild to moderate, unlike the moderate to intense response observed in the NCG. This highlights the beneficial effects of both PE11 and CP in comparison.

When there is a break in skin continuity, there is an immediate migration of polymorphonuclear cells, which perform phagocytosis of microorganisms and devitalized tissue and stimulate the release of growth factors, chemokines, and cytokines. These substances favor the proliferation and migration of fibroblasts from the wound edges<sup>(13,19)</sup>. The PE11 and PCG groups showed a balanced flow of polymorphonuclear and mononuclear cells on the 7th, 9th, and 11th PO days, which favored the organization of granulation tissue and, consequently, the healing of the lesions.

Other studies have also described the anti-inflammatory effects of propolis, such as its ability to reduce edema and chemotaxis of essential cells for the tissue repair process<sup>(20-21)</sup>.

The observed results in the evaluation of fibroblasts, collagen deposition, and neovascularization in the PE11 and PCG groups demonstrated the beneficial effects of both tested products on tissue repair. During the proliferative phase, fibroblasts produce type III collagen, which, with the help of macrophages,



transforms into type I collagen. This confers resistance to the integumentary system, as these components are responsible for the repair of connective tissue and provide support to the epidermal cells. These factors are also relevant for the healing of acute or chronic wounds<sup>(22-23)</sup>. In this research, a slightly superior response was observed in the group treated with green propolis, as 66.66% of the animals in this group had their wounds healed by the 11th PO day.

Ideal dressings are those that are easy to apply and remove, prevent lesion contamination, and promote adequate granulation tissue formation, among other characteristics. Although specific samples for the analysis of pathogenic microorganisms were not collected, the absence of infection signs in the lesions observed by the researchers and the results obtained in this study allow us to infer that the green propolis-based powder product inhibited the proliferation of microorganisms that could cause an infectious process during the 11 days of evaluation.

Overall, our findings pave the way for clinical trials to assess safety and efficacy in humans (*in vivo* studies) or with human cells (*in vitro* studies) as an alternative treatment for acute and/or chronic wounds.

## CONCLUSION

The results of this experimental research indicated that the topical use of a product formulated with an 11% hydroalcoholic extract of green propolis enhanced the healing process of surgically induced lesions in animals, as observed through macroscopic and histological wound analysis.

This study contributed to the expansion of knowledge regarding the use of green propolis and its role in the skin lesion healing process. Therefore, the formulation developed in this research could potentially be a useful dressing for the treatment of acute wounds. However, it is still necessary to conduct studies involving humans to ensure the resin's safe and effective use.

A limitation of this study was the exposure of the surgical lesion beds during the experiment due to the impossibility of occlusion with secondary coverings at the time. This may have contributed to the formation of crusts and necrosis in some animals by keeping the newly formed granulation tissue exposed to ambient air, causing the wound bed to dry, as well as allowing greater exposure to environmental microorganisms and reducing the contact time of the tested products with the lesions. Therefore, future research must occlude lesions for a precise evaluation of product effectiveness and to minimize healing delays.

## REFERENCES

1. Gomes FP, Galvão NS, Albuquerque AD. Perfil sociodemográfico e clínico dos pacientes com lesões agudas e crônicas em atendimento ambulatorial. *Revista Eletrônica Acervo Saúde*. 2021;13(2):e5196. <https://doi.org/10.25248/reas.e5196.2021>.
2. Moreski DAB, Leite-Mello EVS, Bueno FG. Ação cicatrizante de plantas medicinais: um estudo de revisão. *Arq. ciências saúde UNIPAR*. 2018;22(1):63-69. <https://doi.org/10.25110/arqsaude.v22i1.2018.6300>.
3. Anjum SI, Ullah A, Khan KA, Attaullah M, Khan H, Ali H, et al. Composition and functional properties of propolis (bee glue): a review. *Saudi J Biol Sci*. 2019;26(1):1695-1703. <https://doi.org/10.1016/j.sjbs.2018.08.013>
4. Rojczyk E, Klama-Baryla A, Labus W, Wilemska-Kucharzewska K, Kucharzewski M. Historical and modern research on propolis and its application in wound healing and other fields of medicine and contributions by polish studies. *J Ethnopharmacol*. 2020;262:113159. <https://doi.org/10.1016/j.jep.2020.113159>
5. Chen L, Liu Y, Chen L, Zhang X, Feng F, Zhang F. Determination of phenolic compounds in Chinese poplar propolis, Brazil green propolis and poplar gum by high performance liquid chromatography-quadrupole-time-of-flight mass spectrometry and preliminary study of the identification of adulteration. *Se Pu*. 2019;37(1):40-45. <https://doi.org/10.3724/SPJ.1123.2018.09003>.
6. Dambros Filho E, Hey A, Dangui AZ, Sanches CGS, David LE, Carraro E, et al. Estudo comparativo da atividade antimicrobiana *in vitro* de extratos e óleo essencial de *Baccharis dracunculifolia* D.C contra *Escherichia coli* e *Staphylococcus aureus*. *Braz J Dev*. 2021;7(1):5830-5848. <https://doi.org/10.34117/bjdv7n1-396>

7. Oryan A, Alemzadeh E, Moshiri A. Potencial role of propolis in wound healing: biological properties and therapeutic activities. *Biomed Pharmacother.* 2018;98(1):469-483. <https://doi.org/10.1016/j.biopha.2017.12.069>.
8. Salgueiro FB, Castro RN. Comparação entre a composição química e a capacidade antioxidante de diferentes extratos de própolis verde. *Quim. Nova.* 2016;39(10):1192-1199. Disponível em: <https://doi.org/10.21577/0100-4042.20160136>.
9. Stelton S. Stoma and peristomal skin care: a clinical review. *Am J Nurs.* 2019;119(6):38-45. <https://doi.org/10.1097/01.NAJ.0000559781.86311.64>.
10. Baysan U, Elmas F, Koç M. The effect of spray drying conditions on physicochemical properties of encapsulated propolis powder. *J Food Process Eng.* 2019;e13024. <https://doi.org/10.1111/jfpe.13024>.
11. Andrade JKS, Denadai M, Andrade GRS, Nascimento CC, Barbosa PF, Jesus MS, Narain N. Development and characterization of microencapsules containing spray dried powder obtained from Brazilian brown, green and red propolis. *Food Res Int.* 2018;109:278-87. <https://doi.org/10.1016/j.foodres.2018.04.048>
12. Zomer HD, Trentin AG. Skin wound healing in humans and mice: challenges in translational research. *J Dermatol Sci.* 2018;90(1):3-12. <https://doi.org/10.1016/j.jdermsci.2017.12.009>.
13. Borges EL, Saar SRC, Magalhães MBB, Gomes FSL, Lima VLAN. *Feridas: como tratar.* 2. ed. Belo Horizonte: Coopmed; 2010.
14. Amorim GL, Guillen MRS, Vieira PC, Barcelos LS, Borges EL. Contributions of nurses in basic research: dressing fixation model for excisional cutaneous wounds of mice. *Estima (online).* 2021;19:e1221. [https://doi.org/10.30886/estima.v19.1038\\_IN](https://doi.org/10.30886/estima.v19.1038_IN).
15. Coelho MMF, Menezes LCG, Oliveira SKP, Bonfim ADAC, Cavalcante VMV, Moraes JT, et al. Healing rate in diabetic foot ulcers treated with biomembrane and hydrocolloid powder: randomized clinical trial. *Estima (online).* 2021;19:e0621. [https://doi.org/10.30886/estima.v19.986\\_IN](https://doi.org/10.30886/estima.v19.986_IN)
16. Mehl AA, Schneider B Jr, Schneider FK, Carvalho BHK. Measurement of wound area for early analysis of the scar predictive factor. *Rev. latinoam enferm.* 2020;28e:3299. <http://dx.doi.org/10.1590/1518-8345.3708.3299>
17. Mezdari TJ, Leite MF, Staack Júnior MC, Colchon PH, Balan AB, Zanatta ML, et al. Evaluation of the contraction of cutaneous wounds in wistar rats treated with Brazilian green propolis gel. *Latin American journal of pharmacy.* 2009 [citado em 16 agosto 2023];28(5):762-7. Disponível em: <http://sedici.unlp.edu.ar/handle/10915/7833>
18. Batista LLV, Campesatto EA, Assis MLB, Barbosa APF, Grillo LAM, Dornelas CB. Comparative study of topical green and red propolis in the repair of wounds induced in rats. *Rev. Col. Bras. Cir.* 2012;39(6):515-520. <http://doi.org/10.1590/s0100-69912012000600012>
19. Souza PG, Castro MS, Silva LP. A biologia da proliferação fibroblástica: a excessiva deposição extracelular de colágeno durante o reparo de lesões na pele. *Braz J Dev.* 2021;7(3):28989-29010. <https://doi.org/10.34117/bjdv7n3-560>.
20. Rahal SC, Bracarense APFRL, Tanaka CY, Grillo TP, Leite CAL. Utilização de própolis ou mel no tratamento de feridas limpas induzidas em ratos. *Arch. vet. sci.* 2003;8(1):61-67. <http://dx.doi.org/10.5380/avs.v8i1.4018>
21. Torres MLM, Lima BPN, Marucci MC, Negrão V. Uso de pomada de própolis brasileira tipificada e DMSO para tratamento de feridas cirúrgicas. *Braz. J. Nat. Sci.* 2021 [citado em 16 agosto 2023];4(2):e1422021. Disponível em: <https://www.bjns.com.br/index.php/BJNS/article/view/142/119>
22. Medeiros MMM. Efeitos *in vitro* da papaína em fibroblastos humanos oriundos de pele [Tese]. [São Paulo]: Universidade de São Paulo; 2021. 65 p.
23. Oliveira NR, Silva IA, Pinto RR. Colágeno: uma breve revisão. *Braz J Dev.* 2021;7(11):103346-103355. <https://doi.org/10.34117/bjdv7n11-112>

---

**Responsible editors**

Patrícia Pinto Braga | Editor-in-Chief

Juliano Teixeira Moraes | Scientific Editor

**Note:** Taken from Doctoral Thesis entitled “Healing activity of green propolis extract in the treatment of skin lesions induced in adult wistar rats”.

**Received in:** 26/07/2022

**Aproved in:** 01/07/2023

**How to cite this article:**

Faria TF, Faria RF, Kamada I, Barreto LCLS. Healing of acute wounds treated with green propolis-based powder product. *Revista de Enfermagem do Centro-Oeste Mineiro*. 2023;13:e4796. [Access\_\_\_\_\_]; Available in:\_\_\_\_\_. DOI: <http://doi.org/10.19175/recom.v13i0.4796>